

volume 1 ●
number 1 ●
september 2010 ●
issn 1754-2766 ●

JCD

the international journal of cosmetic dentistry



official journal of the British Academy of Cosmetic Dentistry

in this issue

- Tooth replacement
- All ceramic crown and adjacent veneer
- Anterior bridge
- KISS – Keep it Simple

All ceramic crown and adjacent veneer

Accreditation Case Type 2

Paul Gerrard Dental Technician

Introduction and patient's chief complaint

The patient presented to the practice wishing to enhance the appearance of her smile after her upper central incisors had been traumatised two years previously, leaving them fractured and discoloured.

Summary of clinical information

Trauma to the patient's central incisors had resulted in devitalisation and severe discolouring of the 21 and an incisal fracture of the 11 which was vital but had approximately 40% of the coronal tooth tissue missing. The 21 had also been palatally displaced by about 1.5-2mm. Tooth 21 had already been root treated and further radiographic examination indicated

a potential periapical lesion, although the tooth was asymptomatic. The remaining dentition was healthy.

The aim of treatment was to restore correct form to the 11 and bring 21 labially in line with the existing 11 and 22 whilst restoring a more natural colour.

It was decided that a full all-ceramic crown would replace 11 due to the extent of the fracture, with a veneer on 21. This would allow correction of any form, position and shade issues and satisfy the patients wish for a more aesthetically pleasing smile.

The patient was also informed that 21 would need further root treatment for long term health and stability. However, as the patient only had a two week window to complete treatment, we were unable to carry it out at that point.

Treatment

Prep design

Design followed the manufacturer's recommendation for all ceramic restorations, with an additional consideration for the CAD CAM system used for the frame production. An incisal reduction of 1.5-2mm was undertaken, including smooth round edges to avoid stress points and aid internal milling and fit, with a bevelled margin for ceramic support and optimum frame thickness in this area. As tooth 21 had been palatally displaced, only minimum reduction was required. The stump of the 11 veneer was quite dark so a labial reduction of 1mm was made in the incisal region with an increased reduction of 2mm made in the upper cervical half, which would accommodate greater material thickness in the restoration for colour masking.

Preparation design of 21 also took into account access for re-treatment of endodontic orthograde root filling at a later date.

Material

Ivoclar Emax CAD was the material of choice for this case which has a wide range of indications including crowns, bridges and veneers. Emax has a range of opacity levels and the ability to work to very thin sections (0.3mm) thanks to its strength of 360-400mpa. In my opinion this makes Emax the most flexible, durable and aesthetically pleasing restoration currently available for anterior restoration. As the patient's stump shade on tooth 21 was quite dark, a medium opacity block (MO1) was chosen. This was deemed

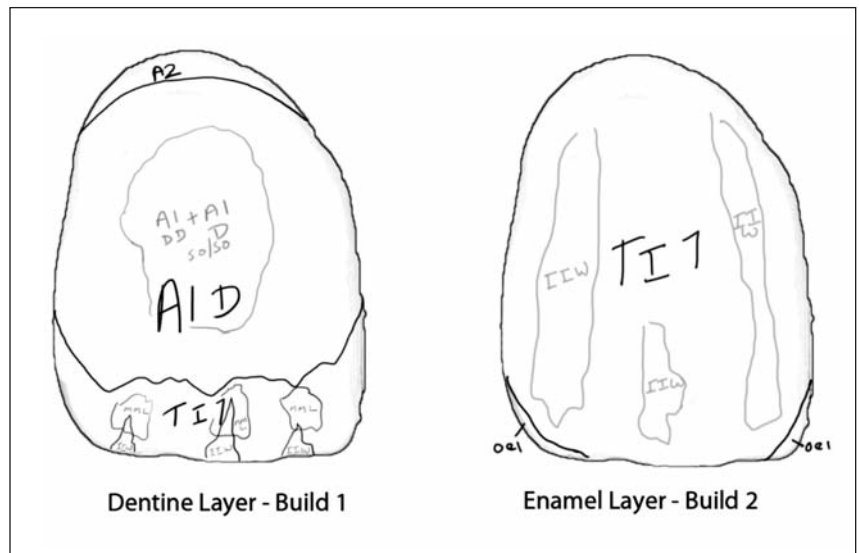
Figure 1a: Copy of lab prescription including shading diagram

sufficient to mask the underlying colour and achieve a final shade in the region of A1. The same block was also used for 11 to help maintain a uniform colour between the two restorations.

Production of model

The impression was first sprayed with a wetting agent to aid the flow of die stone and help reduce bubble formation. The type 4 die stone Fuji Rock Optiscan was chosen for its low expansion, strength and scanning properties which aid accuracy during the cad cam fabrication of the framework. The die stone was mixed under 3.5bar vacuum for 40 seconds then poured into the impression to a sufficient thickness to allow removal of the cast without breakage. This was allowed to set for 1hr. The cast was then removed and trimmed on a dry trimmer to avoid any additional wetting and expansion of the stone. To construct the sectioned model, holes were drilled with an aman pindex unit. A small amount of glue

Figure 1b: Copy of lab prescription including shading diagram



was applied to the Pins from the crosspin system which were then placed into the holes and sprayed with an activator to set the glue. The base was then sprayed with a separating agent and plastic sleeves were placed over the pins. The plastic base from the crosspin system was then filled with die stone and a small amount of die stone was

placed around each sleeve, to stop any air pockets forming around them, before seating the model into the base. This was then allowed to set for a further hour before removal. The two parts were then separated and the cast impression was sectioned with a pindex saw to allow removal of the working dies. An additional solid cast was also made

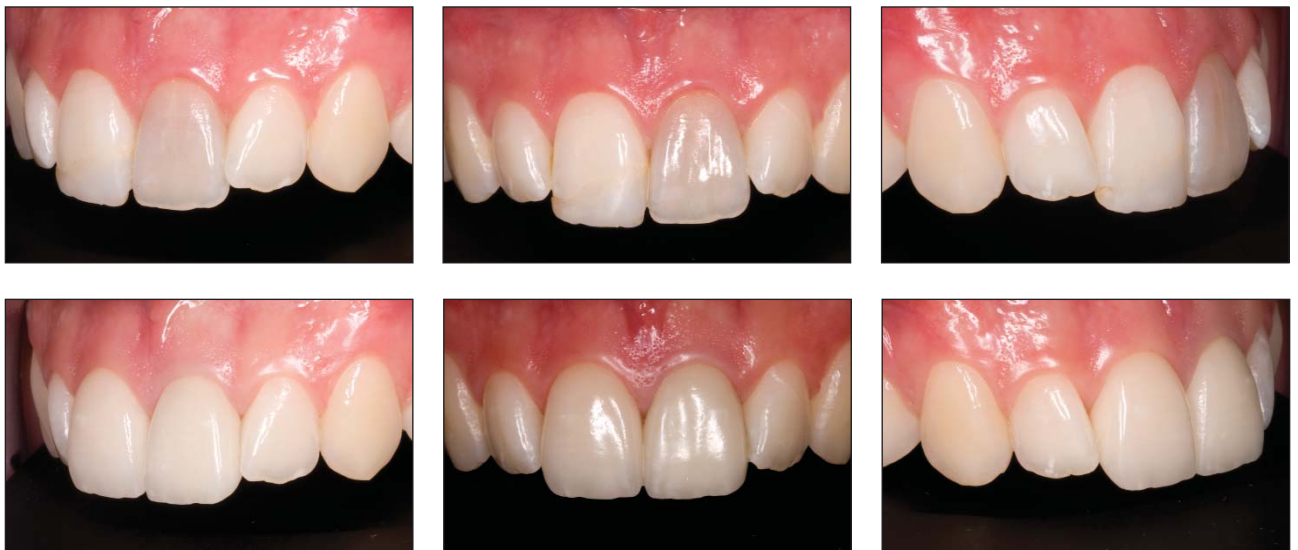
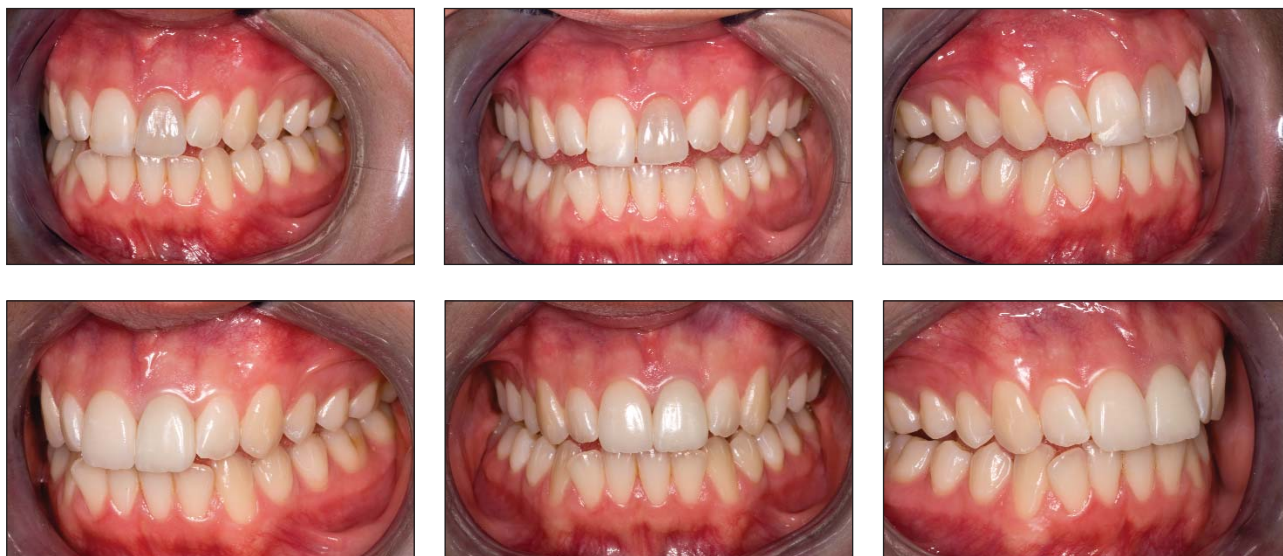
Figure 2a: a-f – Before (above) and after (below) images of the case

Figure 2b: a-f – Retracted: Before (above) and after (below) images of the case



using fujirock EP, which would be used for verification of contacts and tissue contour.

Design and production of frame work

The model die was first trimmed and ditched under x6 magnification to ensure integrity of the margin and allow easy identification of the

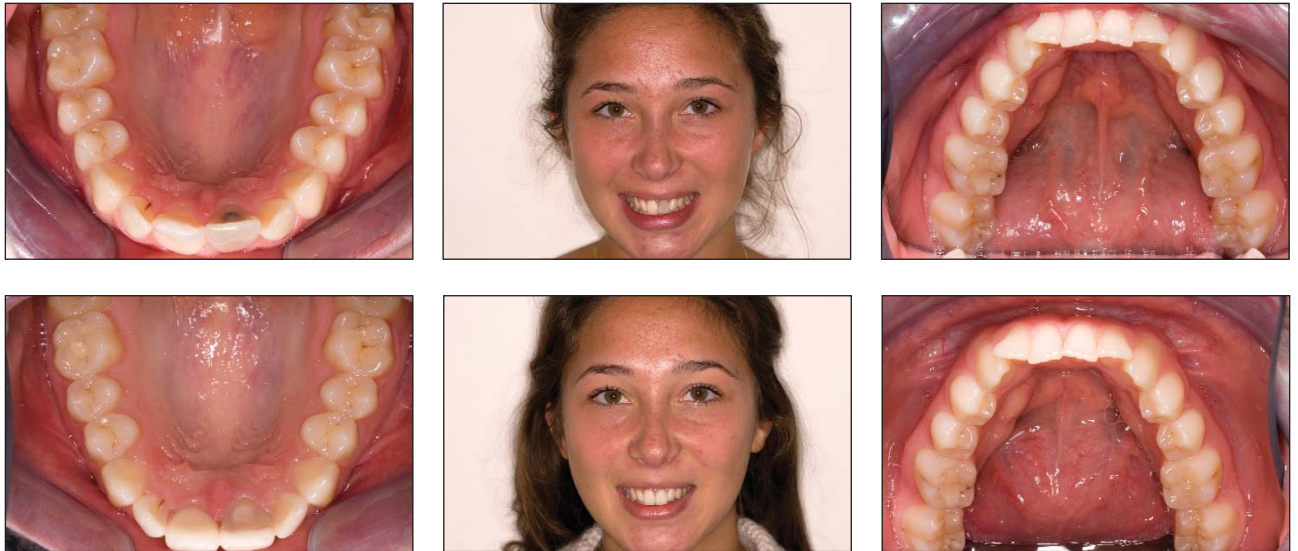
margin by the Cerec In-Lab CAD software to be used. Sectional cuts in the model were filled with scanning putty to avoid any anomalies in the proceeding scan. The model was mounted on the InEos scanning platform and sufficient images were taken to ensure an accurate 3D model. A scan was then taken of the provisional

model which could be superimposed over the preparation model and aid in design of the frames. Margins were defined in the software and frames were designed to approximately 80% of the size of the provisional restorations. These were then milled from an Emax MO1 block via the MCXL milling unit. After approx 10 minutes the completed

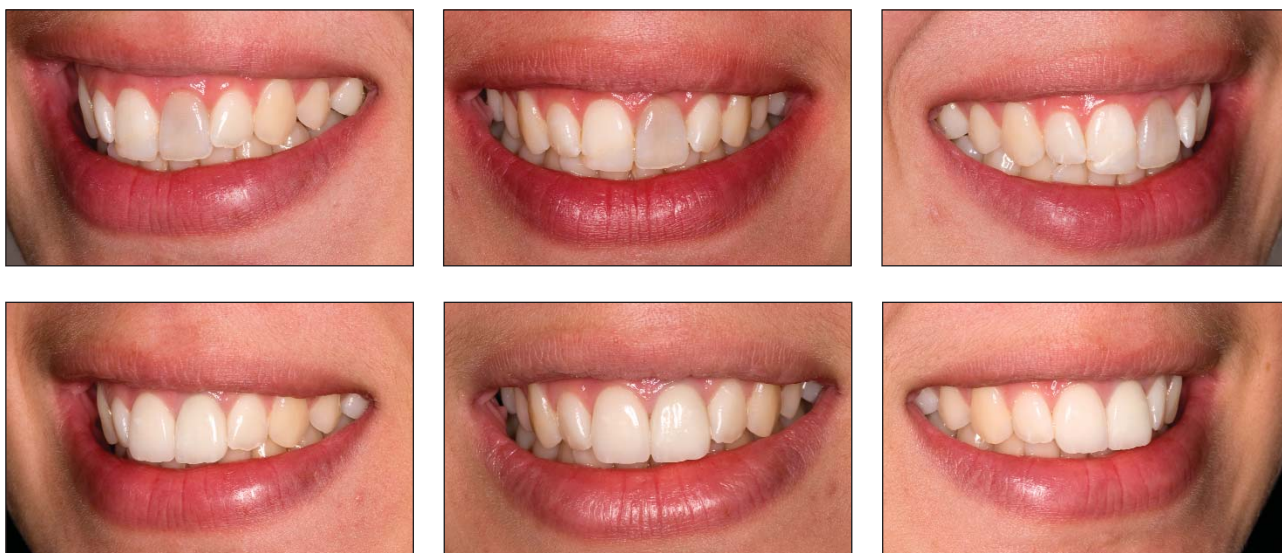

Figure 2c: a-f – Smile: Before (above) and after (below) images of the case

Figure 2d: a-f – Full face, upper occusal and lower occusal: *Before (above) and after (below) images of the case*



frames were removed from the milling chamber and the fit was checked on dies with blue marker under magnification. It was then necessary to sinter the frames which transform them from their blue lithium metasilicate phase into the final lithium disilicate state, achieving their final shade and strength. The frames were filled with

object fix putty which supports them during the sintering processes and placed onto the sintering tray. A 45 minute sintering cycle was then conducted at 8500C before allowing the frames to cool to room temperature. The fit was checked again on the dies and the margins were then thinned out to create a smooth emergence profile.

Layering of ceramic

A base shade of A1 was chosen with a slight A2 neck. This was slightly brighter than the laterals to create the illusion of dominance in the central region and aid the three dimensional appearance of the arch.

A putty incisal index was fabricated against the provisional model into which the working model could be seated. This would then provide a template for the incisal form of the build up. The frames were first moistened with glaze liquid and dusted with a fine layer of A1 deep dentine which was then fired on a regular dentine cycle but with a slower climb rate, which allows the particle sizes of the ceramic to mature more slowly and create an optimal bond to the frames.

Without this layer, any additional layers run the risk of cracking or delamination. The grainy surface also helps to refract light as it passes through the ceramic. A thin wash of stain was then applied to

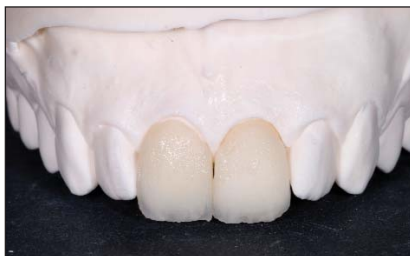

Figure 3: a – Bisque 1

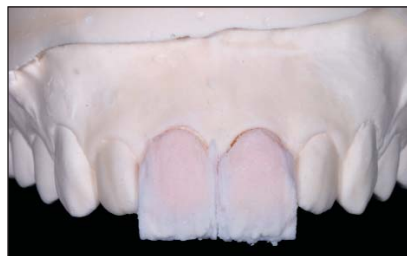

Figure 3: c – Build 1

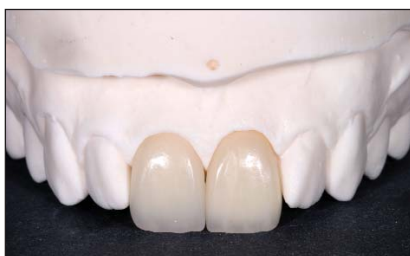

Figure 3: b – Bisque 2

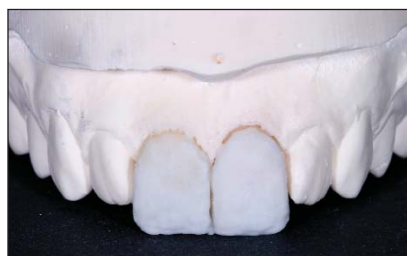

Figure 3: d – Build 2

the frames and fixed with a low temperature firing cycle, which gave the frames the desired shade.

A thin band of A2 dentine was applied to the cervical third and a mixture of A1 Deep Dentine and A1 Dentine was applied to the mid region to increase chroma slightly and help mask the underlying stump colour. A1 dentine was used to cover the rest of the frames. Translucent Incisal 1 was placed at the mesial and distal sides of each unit and also along the incisal edge approximately 1mm longer than the incisal index to allow for shrinkage.

Some small wedges were removed from the incisal edge which were filled with Inter Incisal White (IIW), and some mamelons were created with MM Light, which would break up the monochromatic appearance of the incisal edge. The restorations were then fired. On the second build, IIW was used to highlight the mesial and distal line angles and OE1 which

is a blue opalescent enamel, was used on the incisal corners. The whole surface was then covered in a thin layer of T1. Mesial and distal edges were built out slightly to allow precise modification of contacts. A second firing cycle was then carried out with a slight temperature reduction to limit any further shrinkage of the previous layer. This two-stage build up technique allows greater control of shrinkage and modification of any internal effects before the final enamel layer is applied, thus avoiding a complete restart of the ceramics should the internal effects need intensifying or reducing.

Once the veneers were re-fitted to the solid model and any shape modifications made using the incisal index for reference, the surface was smoothed with a fine wet diamond and primary anatomy was created. A rubber wheel was then used to smooth the surface further and some fine secondary anatomy was added.

Some white/cream stain was then applied to create some small decalcification areas and this was fixed with a low fusing cycle, followed by application of glaze liquid and firing cycle to seal the surface of the ceramic. The restorations were then lightly buffed on a lathe with a fine synthetic pumice to reduce plaque adhesion and achieve the final desired surface lustre.

Acknowledgement

I am grateful to Neil Gerrard who carried out the clinical work for this case.

Further reading

- Bühler-Zemp P, Völkel T. Scientific Documentation IPS. e.max® Press, 2007.

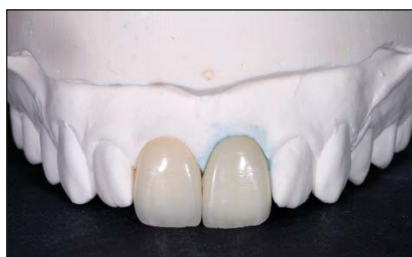

Figure 3: e – Fit on model

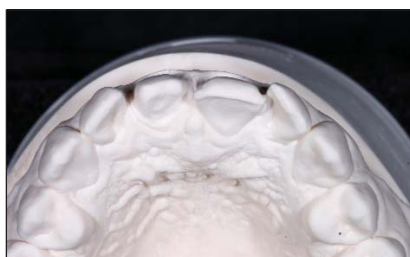

Figure 3: g – Model occusal

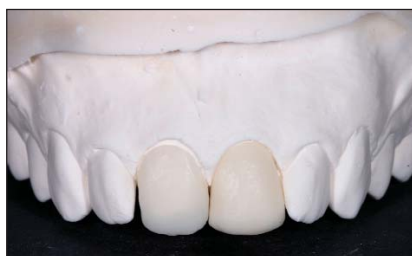

Figure 3: f – Model frames

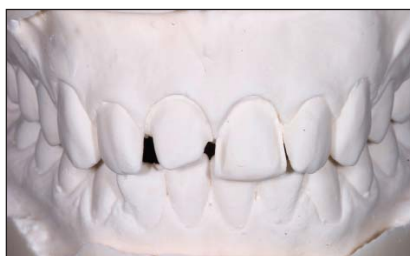

Figure 3: h – Model articulated